



Management of Thoracic Wall Trauma in a Goat: A Case Report

**Rohit Kumar ^{a++*}, Sanjay ^{a#}, Lokesh ^{a#}, Amit Kumar ^{a++},
Deepti Sharma ^{a++}, Deepti Bodh ^{a++} and Adarsh Kumar ^{a†}**

^a Department of Veterinary Surgery and Radiology, DGCN COVAS, CSKHPKV, Palampur, H.P. India.

Authors' contributions

This work was carried out in collaboration among all authors. All authors read and approved the final manuscript.

Article Information

DOI: <https://doi.org/10.9734/acri/2025/v25i61255>

Open Peer Review History:

This journal follows the Advanced Open Peer Review policy. Identity of the Reviewers, Editor(s) and additional Reviewers, peer review comments, different versions of the manuscript, comments of the editors, etc are available here: <https://pr.sdiarticle5.com/review-history/136718>

Case Report

Received: 27/03/2025

Accepted: 29/05/2025

Published: 03/06/2025

ABSTRACT

Thoracic wall rupture is a rare but serious condition in ruminants which can occur because of trauma, leading to respiratory distress, subcutaneous emphysema and compromised thoracic integrity. The present communication describes the successful surgical management of thoracic rupture in a goat. The case was presented with a history of a wound on the right lateral thoracic region with the respiratory distress after returning of the animal from grazing. On clinical examination and radiography, it was diagnosed as a case of thoracic rupture with the presence of haemothorax. So, an immediate surgical repair of the thoracic rupture was done and a chest tube for intermittent thoracocentesis was placed to drain the blood from the pleural space postoperatively. The chest tube was taken out after 3 days and the sutures were removed after 14 days. The animal recovered uneventfully.

⁺⁺ Assistant Professor;

[#] PG Scholar;

[†] Professor;

*Corresponding author: Email: rkrohitkumar224@gmail.com;

Keywords: Goat; thoracic rupture; punctured wound; haemothorax; chest tube.

1. INTRODUCTION

Thoracic injury is a common cause of death in animals following trauma. Despite this, the thoracic wall is naturally resilient and often remains relatively unscathed, even when there is substantial damage to internal thoracic structures. The nature of the thoracic injury is largely determined by the pressure gradient across the diaphragm at the moment of trauma (MacPhail, 2020). Thoracic injuries in goats can involve damage to the thorax, ribs, lungs or other viscera in the area. These injuries can result from trauma, such as falls, struck by heavy objects, dog bites or accidents during handling or transport. Penetrating wounds on thorax are rare in cattle and goats which can sometimes lead to subcutaneous emphysema, respiratory difficulty or pneumothorax. Thoracic trauma causes shock along with the cardiovascular and respiratory injuries. The emergency suturing of the thoracic region and administration of antibiotics helps in the survival of such cases (Shivaprakash, B. V. 2011). The common radiographic findings in the thoracic punctured wounds are subcutaneous emphysema, pulmonary infiltrates (contusion), pneumothorax and rib separation (McKiernan et al., 1984). Since thoracic trauma can result in extensive organ damage, a global approach should be taken to manipulate vital thoracic organs and successfully manage the trauma (Looney, 2001; Fossum, 2002; Kirpensteijn, 2002; Pelosi et al., 2008). Following penetrating thoracic trauma, a pressure gradient between the negatively pressured pleural cavity and atmospheric air develops until either the defect in the body wall is sealed or the pressure equalizes (Pollock, 2008). This leads to respiratory compromise. Due to change in the pressure gradient the patient has to make more respiratory efforts due to which such cases needs immediate surgery to improve the ventilation of the animal. The present communication describes successful management of the punctured wound in the thoracic region caused by unknown trauma in a goat.

2. PRESENTATION OF CASE

An adult goat was presented with a lacerated wound in the right thoracic region (Plate 1) observed by the owner after the return of the animal from grazing. Upon clinical examination a paradoxical respiration was observed in the animal and when the lacerated wound was

examined after clipping the hairs around the wound it was found that the thoracic muscles are completely torn at the level of the wound and the air is coming out from the punctured wound during the expiration. So, an immediate decision was taken to surgically repair the open thoracic wound. The heart rate and rectal temperature was in the normal physiological range. Although the respiratory rate was slightly depressed and the heart sounds are diminished in the auscultation.



Plate 1. Location of the punctured thoracic wound

Pre-operatively mask oxygenation was done after covering the punctured wound with sterile swab to improve the ventilation of the animal. The respiration improved after oxygenation and covering of the wound. After the stabilization of the animal, radiography was performed. In the left lateral radiograph, radiopacity was noted in the ventral area of the thoracic cavity indicative of the presence of the fluid or blood (Plate 2). The fluid therapy was done using Isotonic crystalloid solutions (lactated Ringer's solution) to maintain electrolyte balance and provide sustained volume resuscitation to prevent the animal from going into hypovolemic shock. For surgical intervention, the site was aseptically prepared. The torn muscles were sutured with Polygalactin 2-0 under local infiltration of 2% lignocaine as the animal was not a good subject for general anaesthesia due to the respiratory and cardiovascular depression and a chest tube was also placed (Plate 3). After suturing the intercostal muscles lignocaine was administered in the intercostal muscles for the post-operative pain management. The skin was then sutured with non-absorbable suture polyamide 2-0.

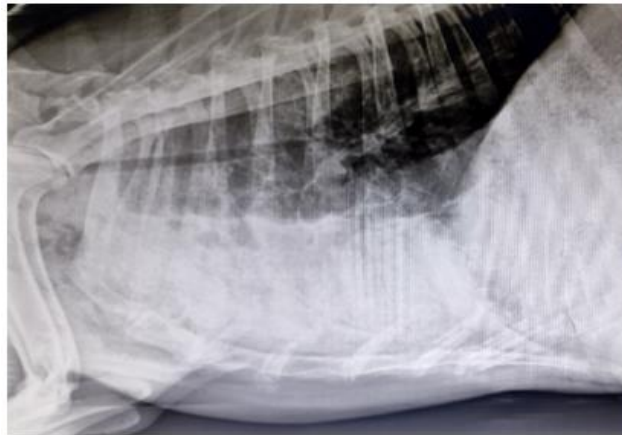


Plate 2. Pre-operative radiograph

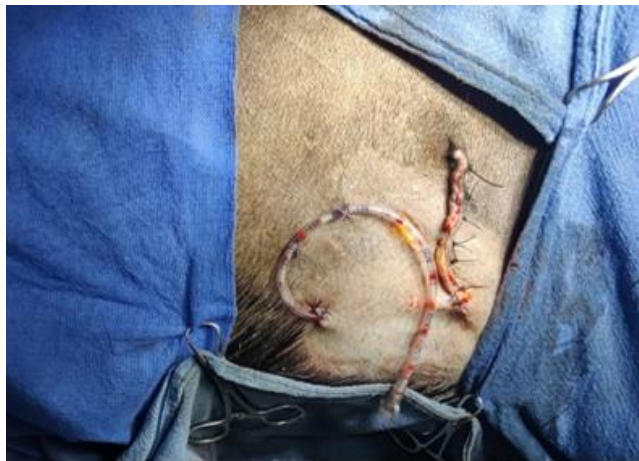

Plate 3. Chest tube placement

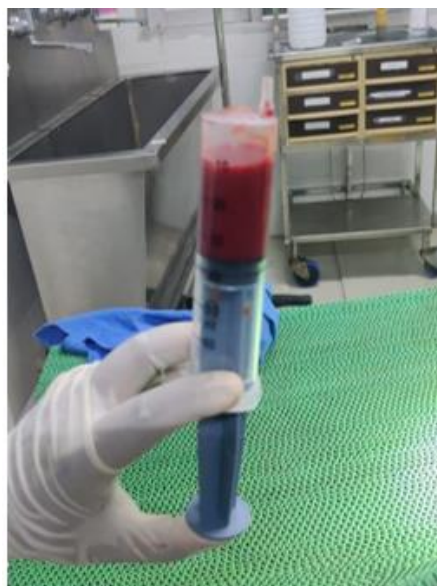

Plate 4. Blood retrieved through chest tube



Plate 5. 14th day post-operatively

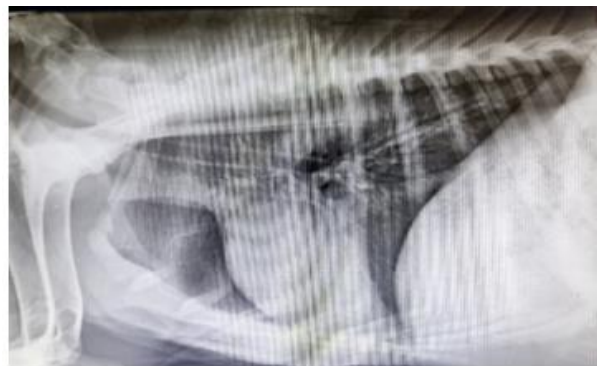

Plate 6. 1.5 months post-operative radiograph

Post-operatively, the animal was kept on inj. Dicrysticine @ 5 mg/kg b.wt i/m b.i.d. for five days and inj. Melonex @ 0.2 mg/kg b.wt i/m o.i.d for three days. Through the chest tube around 15 ml blood was retrieved immediately after surgery (Plate 4). The chest tube was left *in situ* for next 3 days till no retrieval of blood from the thoracic cavity. The skin sutures were removed on the 14th day post-operation. The animal recovered successfully with no complication (Plate 5). After 1.5 months' post-surgery the radiograph revealed no signs of haemothorax (Plate 6).

3. DISCUSSION

Thoracic trauma cases are always considered urgent because they can compromise the cardiorespiratory system. As a result, immediate stabilization procedures are essential in managing such injuries (Salci et al., 2010 and

Looney, 2001). The cranial thoracic wounds can be life threatening for the animal and all the signs of respiratory depression should be carefully assessed before going for surgical repair (Rojman et al., 2009). Respiratory depression is commonly observed in cases where the thoracic wall is breached. Therefore, oxygen therapy is mandatory in such cases to fulfill the need of oxygen in the animal prior to surgical repair. Salci et al., 2010 reported that similar cases were given mask oxygen therapy in their study. In cases involving penetrating thoracic wall wounds, a sterile, occlusive bandage can be applied prior to surgical intervention so that diagnostic radiography and oxygen can be easily performed for the stabilization of the animal.

Radiography plays a vital role in diagnosing any thoracic pathologies such as flail chest, pneumothorax, haemothorax etc. in such cases

with thoracic ruptures (Brühl-Day, 2002). In case of haemothorax or pneumothorax confirmed in the radiograph chest tube placement is done to relieve the accumulated air or blood in the pleural space (Pollock, 2008). Pollock, 2008 also documented that the animals with open thoracic wounds are poor subjects for the general anaesthesia because of the respiratory and cardiovascular depression. In the present case, physical examination along with radiographic findings pointed towards thoracic trauma along with the presence of haemothorax which was clearly visible in the radiograph (increased radiopacity in the ventral portion of the thorax, also the heart margins are not visible because of this increased radiodensity leading to unclear cardiac silhouette). The presence of the haemothorax warranted the placement of chest tube to remove the blood/fluid after the surgical procedure to alleviate respiratory distress. This was also documented by de Laforcade, 2002 and Frendin and Obel, 1997 in their study. So, the goat was medically treated with antibiotics and NSAID after the surgical repair along with intermittent thoracocentesis from the chest tube placed during the surgery.

In the surgical repair of thoracic injuries, suturing of the thoracic muscles is a critical step to restore the integrity of the thoracic wall and ensure proper healing. After addressing any internal thoracic injuries (such as lung lacerations or hemothorax), the thoracic muscles that includes the intercostal muscles, external obliques and latissimus dorsi must be carefully re-approximated to prevent any sort of leakage (Fowler, 1973). Absorbable sutures were often preferred for the suturing of the muscles. Interrupted or continuous suture patterns may be used, depending on the extent of the injury and surgeons' preference. In the present case absorbable polygalactin 910 was used for the closure of the intercostal muscles in the simple continuous suture pattern. Lugo, 2006 in his study found that the administration of lignocaine in the intercostal muscles helps in the post-operative pain management which was also followed in this case.

4. CONCLUSION

Thoracic rupture in goats, though a serious and potentially life-threatening condition, can be effectively managed when prompt surgical intervention is undertaken. Early recognition of the injury and swift decision-making to proceed with surgical repair are crucial in improving the

animal's chances of recovery. An essential component of managing such cases was the placement of a chest tube, particularly in the presence of haemothorax to remove the blood from the thoracic cavity intermittently. This procedure is vital in stabilizing the animal both during and after surgery. Furthermore, the administration of a local anesthetic, such as lignocaine, into the intercostal muscles following the completion of suturing plays a vital role in post-operative pain management. By blocking nerve transmission in the affected area, lignocaine provides localized pain relief, reduces stress responses in the animal, and promotes smoother recovery. Adequate pain control not only enhances the animal's comfort but also contributes to better wound healing and a quicker return to normal physiological function.

In summary, the successful management of thoracic rupture relies heavily on timely surgical repair, effective drainage of the thoracic cavity through chest tube placement and appropriate pain control measures like the use of lignocaine. These combined strategies significantly improve the prognosis and overall outcome for the animal.

DISCLAIMER (ARTIFICIAL INTELLIGENCE)

Author(s) hereby declare that NO generative AI technologies such as Large Language Models (ChatGPT, COPILOT, etc.) and text-to-image generators have been used during the writing or editing of this manuscript.

ETHICAL APPROVAL

Animal Ethic committee approval has been collected and preserved by the author(s).

COMPETING INTERESTS

Authors have declared that no competing interests exist.

REFERENCES

- Brühl-Day, R. (2002). Management of the trauma patient. In *27th WSAVA Congress Proceedings*, October 3–6, Sydney, Australia.
- de Laforcade, A. (2002). Management of thoracic trauma. In *Tufts Animal Expo Conference Proceedings*, September 1, Boston, Massachusetts, USA.

- Fossum, T. W. (2002). *Small animal surgery* (2nd ed., pp. 770–773). Mosby.
- Fowler, M. E. (1973). Intrathoracic surgery in large animals. *Journal of the American Veterinary Medical Association*, 162(11), 967–973.
- Freundin, J., & Obel, N. (1997). Catheter drainage of pleural fluid collections and pneumothorax. *Journal of Small Animal Practice*, 38(6), 237–242.
- Kirpensteijn, J. (2002). The role of emergency surgery in thoracic trauma. In *27th WSAVA Congress Proceedings*, October 3–6, Sydney, Australia.
- Looney, L. A. (2001). Thoracic trauma: The do's and don'ts of chest triage. In *Atlantic Coast Veterinary Conference Proceedings*, October 9–11, Atlantic City, New Jersey, USA.
- Lugo, J. (2006). Thoracic disorders. In J. A. Auer & J. Stick (Eds.), *Equine surgery* (3rd ed., pp. 616–623). Saunders Elsevier.
- MacPhail, C. M. (2020). Thoracic injuries. In D. J. Fletcher & E. M. Boller (Eds.), *The veterinary ICU book* (pp. 655–669). CRC Press.
- McKiernan, B. C., Adams, W. M., & Huse, D. C. (1984). Thoracic bite wounds and associated internal injury in 11 dogs and 1 cat. *Journal of the American Veterinary Medical Association*, 184(8), 959–964.
- Pelosi, A., Hauptman, J. G., Eyster, G. E., Beal, M. W., Anderson, L. K., & Olivier, N. B. (2008). Myocardial perforation by a stick foreign body in a dog. *Journal of Veterinary Emergency and Critical Care*, 18, 184–187.
- Pollock, P. J. (2008). Penetrating injuries to the thorax: A clinical challenge. *Equine Veterinary Education*, 20(8), 418–421.
- Rojman, Y. R., Newkirk, E. S., & Grewal, J. S. (2009). Penetrating injury at the thoracic inlet in a Paint-Arab mare. *Equine Veterinary Education*, 21(12), 621–626.
- Salci, H. A. K. A. N., Bayram, A. S., Celimli, N., Caliskan, G. U., Gorgul, O. S., & Kramer, M. (2010). Evaluation of thoracic trauma in dogs and cats: A review of seventeen cases. *Iranian Journal of Veterinary Research*, 11(4), 325–331.
- Shivaprakash, B. V. (2011). A clinical insight into emergency surgeries in ruminants. *Intas Polivet*, 12(2), 129–141.

Disclaimer/Publisher's Note: The statements, opinions and data contained in all publications are solely those of the individual author(s) and contributor(s) and not of the publisher and/or the editor(s). This publisher and/or the editor(s) disclaim responsibility for any injury to people or property resulting from any ideas, methods, instructions or products referred to in the content.

© Copyright (2025): Author(s). The licensee is the journal publisher. This is an Open Access article distributed under the terms of the Creative Commons Attribution License (<http://creativecommons.org/licenses/by/4.0>), which permits unrestricted use, distribution, and reproduction in any medium, provided the original work is properly cited.

Peer-review history:

The peer review history for this paper can be accessed here:

<https://pr.sdiarticle5.com/review-history/136718>